

**Locomotion and Movement**

**Locomotion and movement**

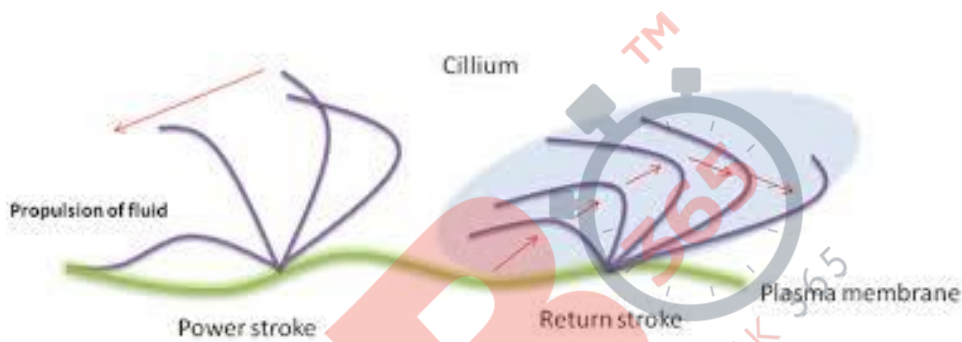
Movement is defined as when organism moves from one location to another location. When movement result in change in position or location, it is known as locomotion. For example, walking, climbing, running etc.

**Types of movement**

Ciliary, amoeboid, and muscular are three types of movement.

**Ciliary movement**

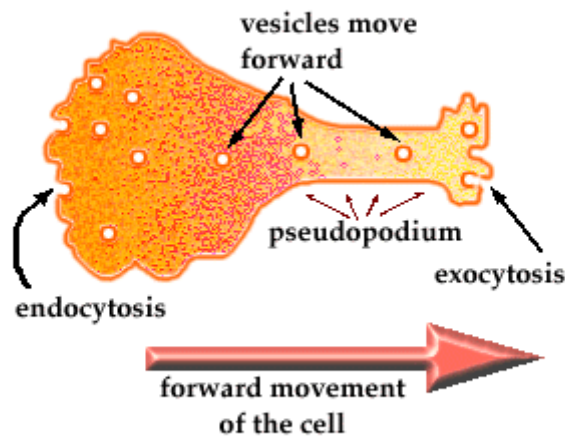
This type of movement occurs in organs lined by ciliated epithelium. It is used to trap dust particles that enter during inhalation. It also helps in movement of ova from the fallopian tube into the uterus.



**Fig. 1. Ciliary movement in *Paramecium***

**Amoeboid movement**

This type of movement is observed in some immune cells such as macrophages, leucocytes etc. It is also observed in *Amoeba*, which moves through pseudopodia.



**Fig. 2. Amoeboid movement in *Amoeba***

**Muscular movement**

Muscular movement is observed in tongue, jaws, limbs etc. For locomotion, muscular, skeletal, and neural system are involved.

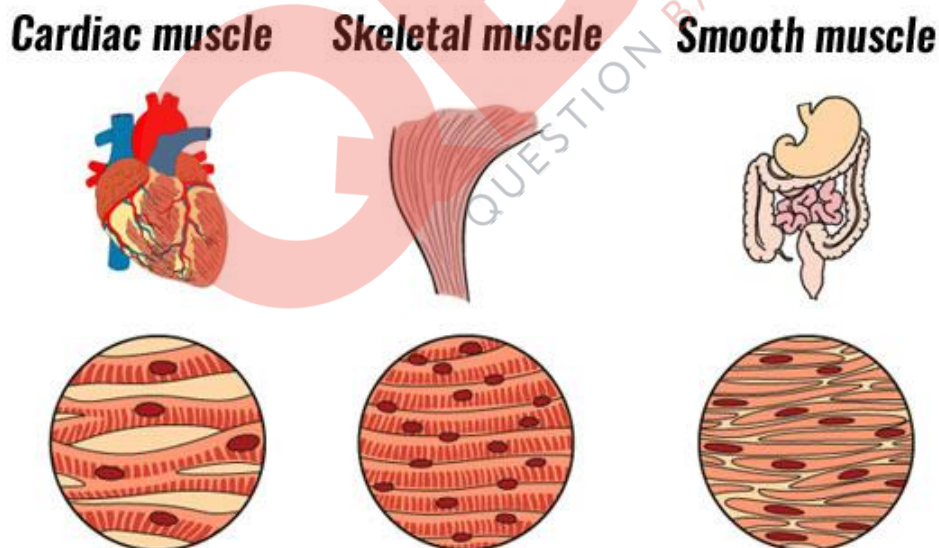
**Muscle**

Muscle or muscular tissue is mesodermal in nature. It is a tissue involved in movement of the body. **Skeletal muscles, visceral muscles, and cardiac muscles are three main types of muscles.**

**Skeletal muscles** are voluntary muscles (under the control of our will) which are under the control of somatic nervous system. They are striated muscles as they have characteristic cross-striations. Muscles are attached to bones via tendons. They are involved in different body movements and body posture.

**Smooth muscles** are also known as visceral muscles. They do not have striations. They control involuntary movements in the body. They are found in the lining of alimentary canal, reproductive tract, etc.

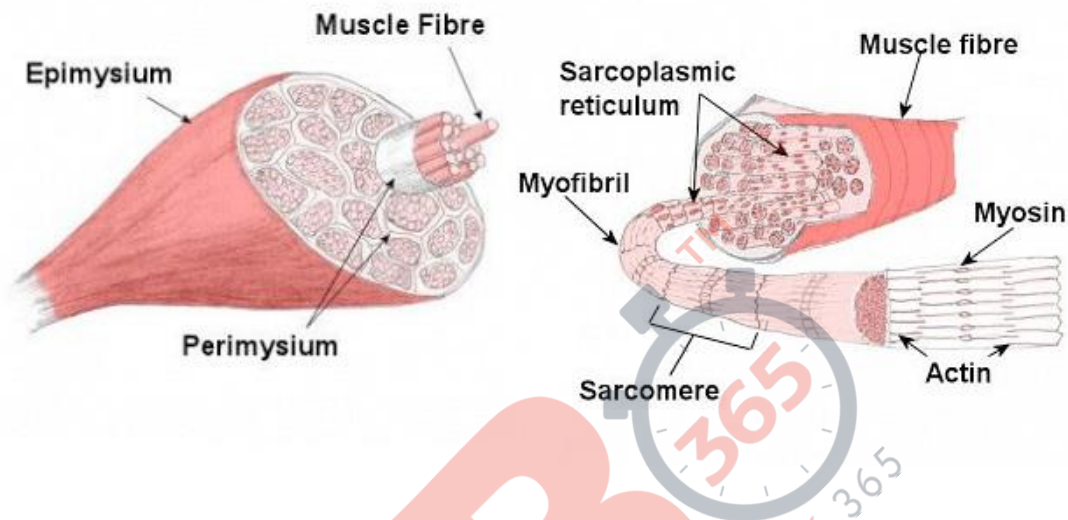
**Cardiac muscles** are muscles of the heart that help in the rhythmic contraction and relaxation of the heart. They are involuntary muscles. They have cross-striations with branching pattern.



**Fig. 3. Types of muscles**

**Structure of the muscle**

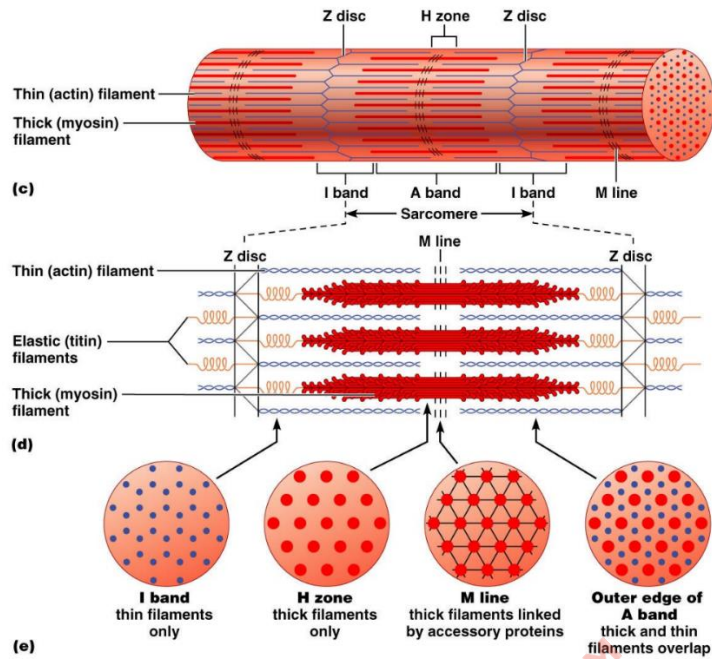
A number of muscle bundles in a skeletal muscles form **fascicle**. Each muscle bundle is made up of a number of **muscle fibers**. The plasma membrane that lines the muscle fiber is known as **Sarcolemma**. Sarcolemma encloses the sarcoplasm. Multiple nuclei found in the muscle fiber is known as **syncytium**. The endoplasmic reticulum of the muscle fiber is known as sarcoplasmic reticulum. Sarcoplasmic reticulum stores calcium ions that participate in muscle contraction. Muscle fiber contain parallelly arranged filaments which are known as **myofibrils or myofilaments**. The fibrous tissue that surround the skeletal muscle is known as epimysium.



**Fig. 4. Structure of the muscles**

The characteristic cross-striations found in skeletal muscles is due to the presence of two proteins- **actin and myosin**. The light bands also known as **isotropic**, contain actin protein, whereas dark band are known as **anisotropic** which contain myosin. Thin filaments are known as actin filaments whereas thick filaments are known as myosin filaments.

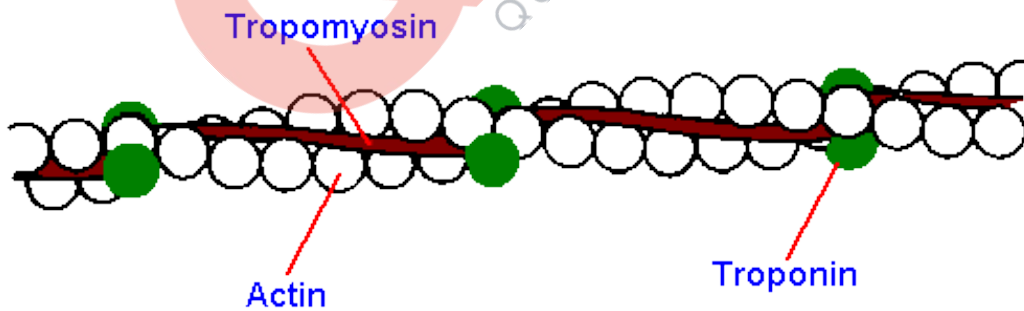
In the center of each actin band there is a stretch of the elastic fiber known as Z-line. The portion of the myofibril between the two successive Z lines is known as **sarcomere**. Sarcomere is known as the functional unit for muscle contraction.



**Fig. 5. Structure of sarcomere**

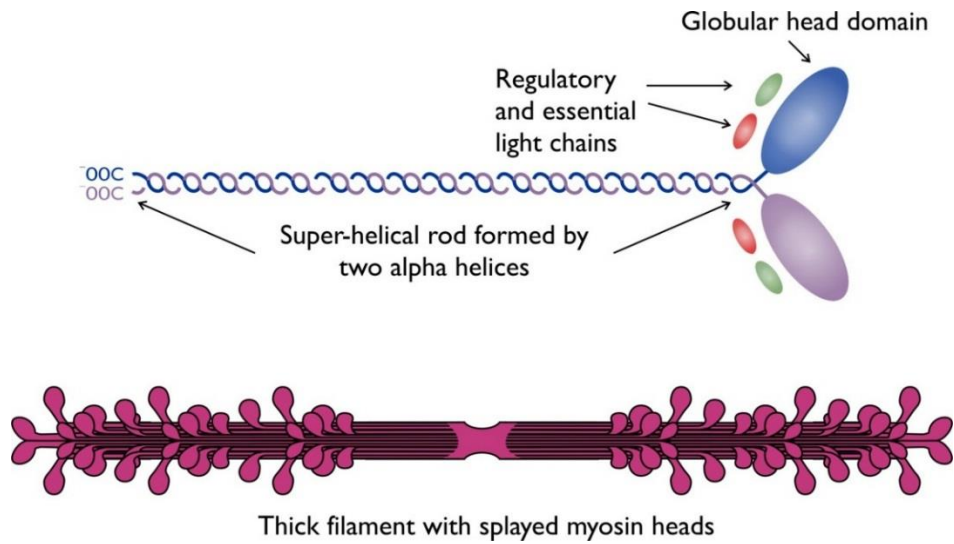
**Structure of contractile proteins**

The two main contractile proteins are actin and myosin. The monomeric unit of actin is known as G actin or globular actin. Polymers of G actin form F actin or F filaments. Two F filaments wrap around each other to form actin molecule. A protein tropomyosin, run around the F actin. Another protein, troponin is distributed at regular intervals on tropomyosin.



**Fig. 6. Structure of the actin**

Monomeric units of myosin are known as Meromyosins. Each meromyosin has two parts: globular head and a long tail.



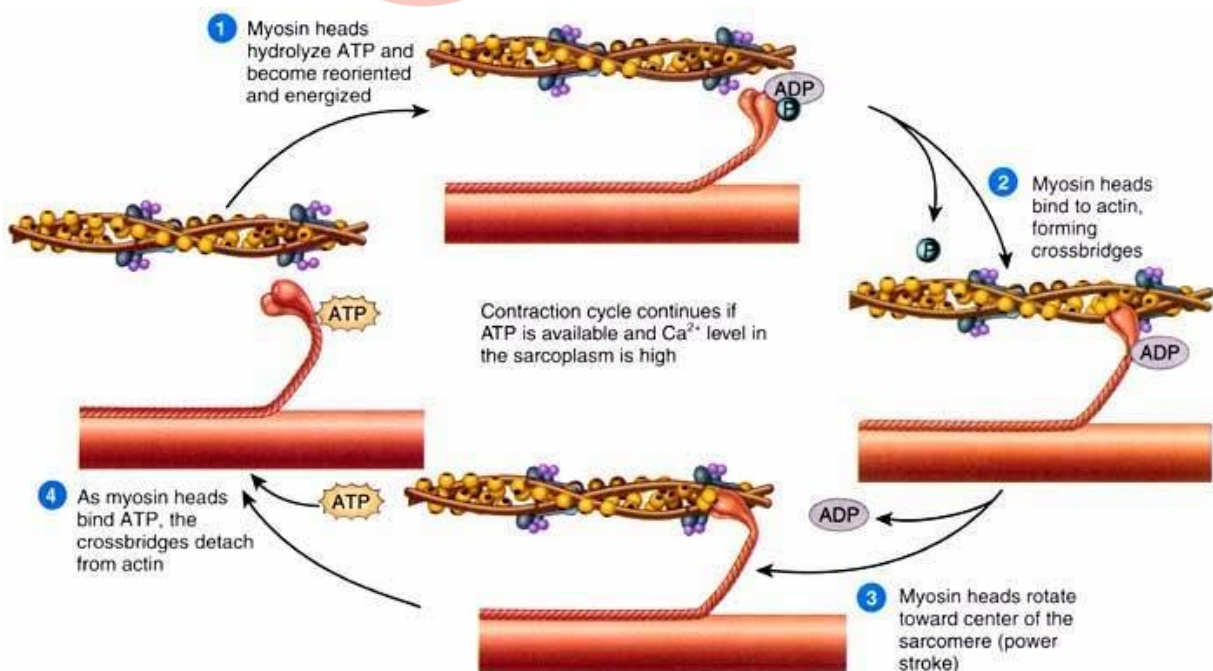
**Fig. 7. Structure of the myosin**

Head has ATPase activity and actin binding site.

**Mechanism of muscle contraction**

The muscle contraction is explained using sliding filament theory. During the muscle contraction, thin filaments slide over thick filaments. Muscle contraction begins when a signal is transmitted from the central nervous system to a motor neuron. The junction between the motor neuron and muscle fiber is known as neuromuscular junction. Release of the neurotransmitter such as acetylcholine at neuromuscular junction generates action potential in the sarcolemma.

Action potential induces the sarcoplasmic reticulum to release calcium ions into the sarcoplasm. Increase in calcium level causes calcium ions to bind to troponin on actin filaments. This unveils the active sites for myosin binding. The ATPase activity of myosin exposes sites to allow cross bridge formation between actin and myosin. This causes shortening of sarcomere to bring the muscle contraction.



**Fig. 8. Sliding filament theory**

The calcium ion are then pumped back into the sarcoplasmic reticulum. This step masks the actin filaments bringing muscles to its original position.

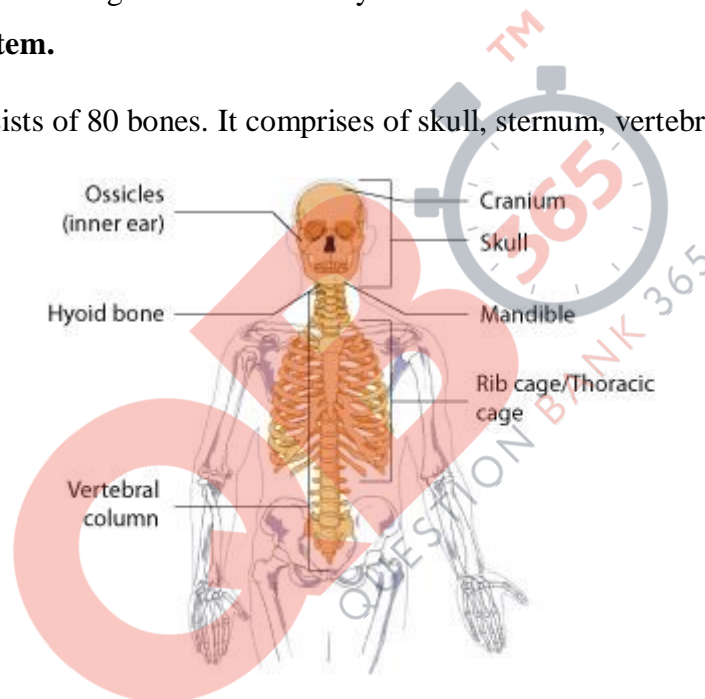
**Lactic acid formation in muscles**

Repeated muscle activation leads to lactic acid accumulation in muscles, for example, during exercise or running. This occurs due to anaerobic breakdown of glycogen in muscles. This causes muscle pain and fatigue.

**Skeletal system**

Skeletal system consists of bones and cartilages. It helps in the movement of the body. Bones are hard due to presence of calcium salts whereas cartilage is flexible because of the presence of chondroitin sulphate. Humans contain 206 bones and few cartilages. The skeletal system has two divisions- **axial skeletal system and appendicular skeletal system.**

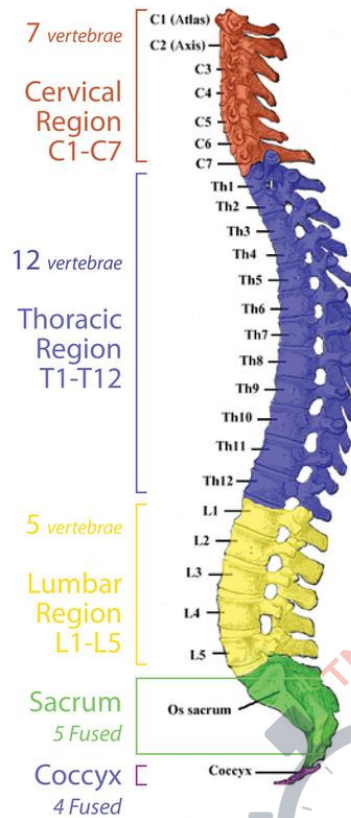
**Axial skeletal** system consists of 80 bones. It comprises of skull, sternum, vertebral column, and ribs.



**Fig. 9. Axial skeletal system**

Skull consist of facial and cranial bones which are 22 in number. Cranial bones are 8 in number which protects the brain. The facial region consists of 14 skeletal elements which form the front part of the skull. Hyoid bone which is U-shaped in structure is present at the base of the buccal cavity. Each middle ear consists of three small bones – Malleus, Incus, and Stapes. They are together known as **Ear Ossicles.**

**Vertebral column** consists of 33 vertebrae. It extends from the base of the skull and forms the main framework of the trunk. Each vertebra has a central hollow part known as neural canal through which the spinal cord passes.

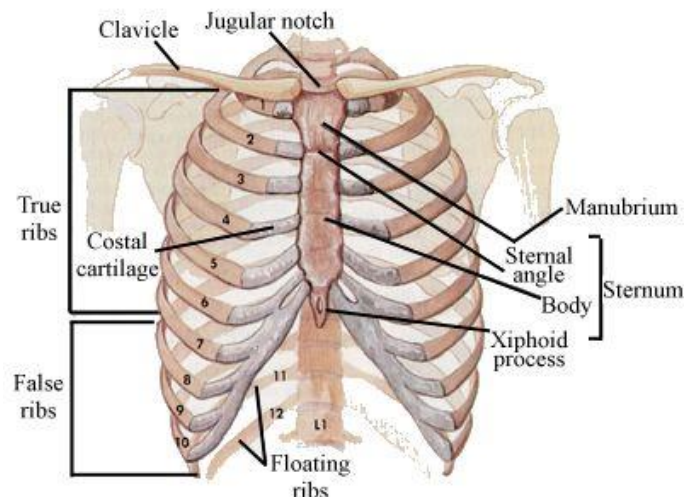


**Fig. 10. Vertebral column**

First vertebra is known as the atlas and it articulates with the occipital condyles. The vertebral column is divided into 7 cervical, 12 thoracic, 5 lumbar, 1 sacral and 1 coccygeal regions starting from the skull. The number of cervical vertebrae is conserved among the mammals.

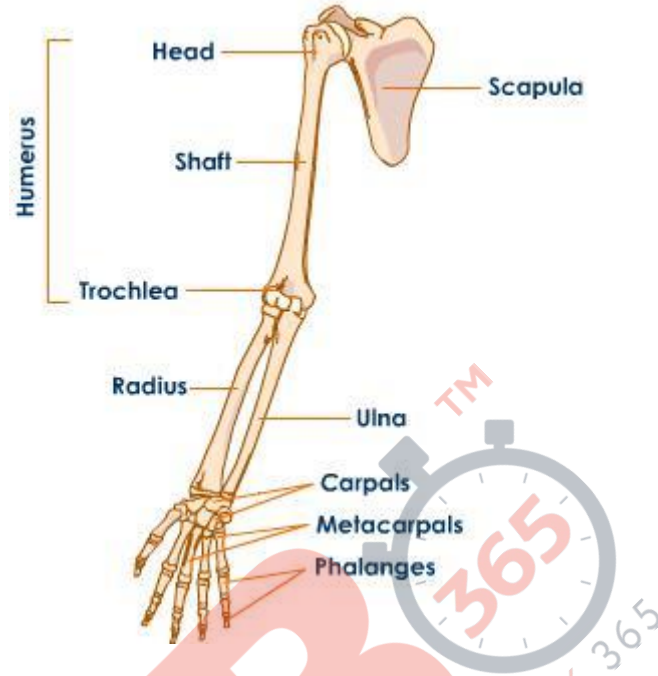
**Sternum** is a flat bone on the ventral midline of thorax. There are 12 pairs of **ribs that are attached to the sternum.**

First seven pairs of ribs are known as true ribs as they are directly attached to the sternum. The 8th, 9th and 10<sup>th</sup> pairs of ribs join the seventh rib instead of joined directly to the sternum. They are known as false ribs. Last 2 pairs (11<sup>th</sup> and 12th) pair of ribs are not connected directly to the sternum, they are known as floating ribs. Thoracic vertebrae, ribs and sternum combines to form rib cage.



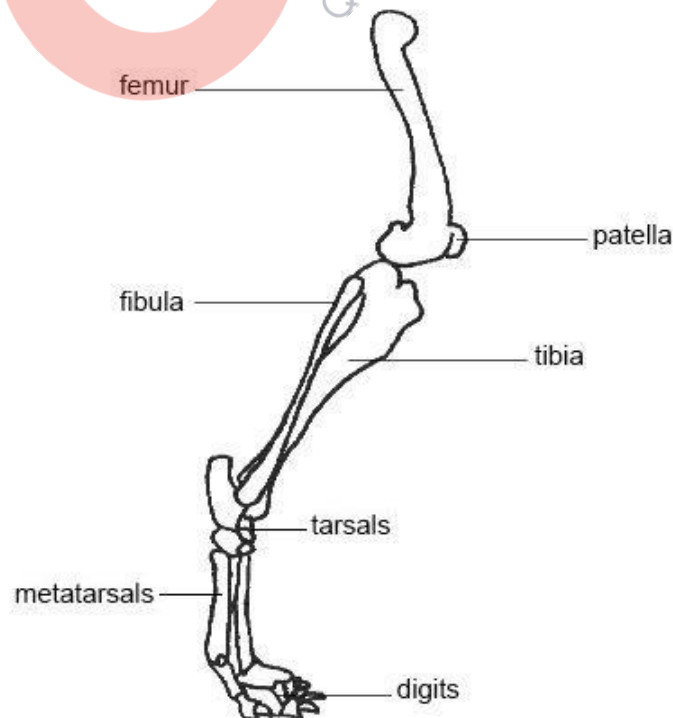
**Fig. 11. Sternum**

**Appendicular skeleton** consists of bones of limbs and girdles. Each limb is made of 30 bones. The bones of the forelimbs or hands are humerus, radius and ulna, carpals (wrist bones which are 8 in number), metacarpals (palm bones which are 5 in number) and phalanges (digits which are 14 in number).



**Fig. 12. Bones of forelimbs**

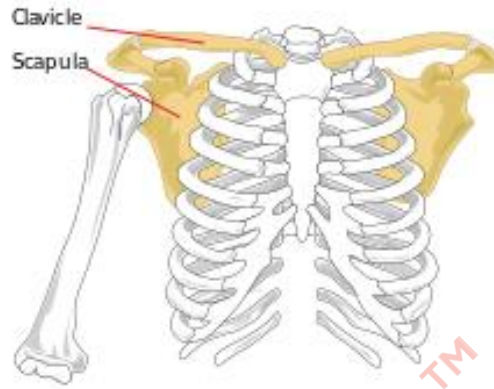
The bones of the hind limbs or legs are- Femur, the thigh bone (longest bone), tibia and fibula, tarsals (ankle bones) which are 7 in number, metatarsals are 5 in number and phalanges are 14 in number. Knee cap contains a cup shaped bone known as patella.





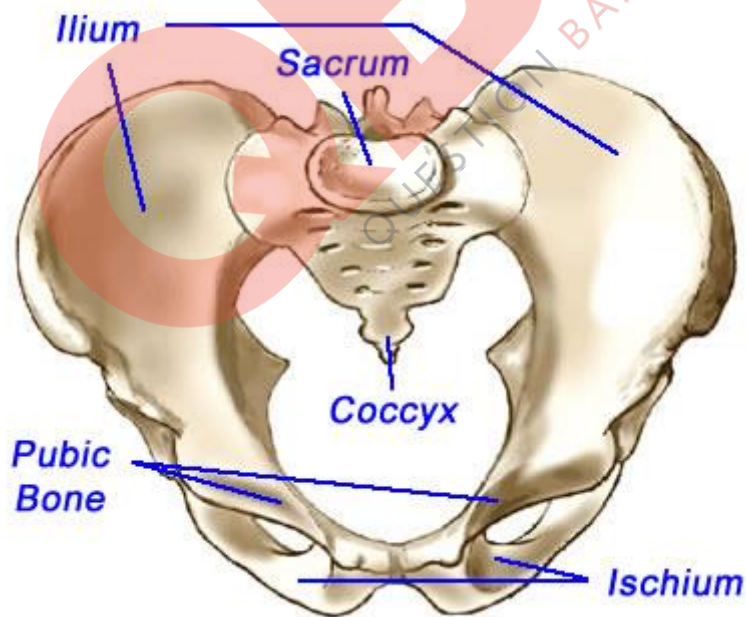
**Fig. 13. Bones of hindlimbs**

**Pectoral girdle** consists of two bones clavicle and scapula. Scapula contains the cavity known as **glenoid cavity** which forms ball and socket joint with the humerus. It articulates with the forelimb bones.



**Fig. 14. Bones of pectoral girdle**

**Pelvic girdle** contains a cup shaped cavity known as **acetabulum** that forms ball and socket joint with the femur. It articulates with the hind limb bones. The muscles of the hip are attached to pelvic girdle.



**Fig. 15. Bones of pelvic girdle**

**Joints:**

Joints are junctions between bones or between bone and cartilage. They are essential for locomotion as they act as fulcrum for the force applied by the muscles to cause movement. There are three major structural types of joints:

1. **Synovial joints:** A characteristic fluid-filled synovial cavity is present between the two bones. This joint gives greater flexibility and more movement. Some examples are hinge joint (knee and elbow), ball and socket joint (shoulder and hip), pivot joint (neck), etc.
2. **Fibrous joints:** Bones join by means of dense fibrous tissues forming sutures. They are immovable. They are seen in the joints between the flat bones of the cranium.
3. **Cartilaginous joints:** Cartilage is present and helps in joining two bones together. These joints are partially movable. They are found between the vertebrae.

**Disorders of the muscular and skeletal system:**

**Myasthenia gravis:** Affects neuromuscular junction. Causes fatigue, weakening and paralysis of skeletal muscles. It is an autoimmune disorder.

**Muscular dystrophy:** A genetic disorder causing progressive degradation of skeletal muscle.

**Tetany:** Low calcium ion levels in body fluid causing rapid spasms in muscles.

**Arthritis:** Inflammation of joints

**Gout:** Accumulation of uric acid crystals in the joint causing joint inflammation.

**Osteoporosis:** Decrease in bone mass causing increased risk of fractures. It is age-related and usually due to decreased oestrogen levels.